

See discussions, stats, and author profiles for this publication at: <https://www.researchgate.net/publication/313025404>

Viability of photo-id as a tool to examine the prevalence of lesions on free-ranging common dolphins (*Delphinus delphis*)

Article in *Aquatic Mammals* · January 2016

DOI: 10.1578/AM.43.3.2017.264

CITATIONS

6

READS

87

1 author:



[Krista Hupman](#)

National Institute of Water and Atmospheric Research

43 PUBLICATIONS 70 CITATIONS

[SEE PROFILE](#)

Viability of Photo-Identification as a Tool to Examine the Prevalence of Lesions on Free-Ranging Common Dolphins (*Delphinus* sp.)

Krista E. Hupman,¹ Matthew D. M. Pawley,¹ Catherine Lea,¹ Charli Grimes,¹
Sabrina Voswinkel,¹ Wendi D. Roe,² and Karen A. Stockin¹

¹Coastal-Marine Research Group, Institute of Natural and Mathematical Sciences, Massey University,
Private Bag 102 904, North Shore MSC, New Zealand
E-mail: k.hupman@massey.ac.nz

²New Zealand Wildlife Centre, Institute of Veterinary, Animal and Biomedical Sciences, Massey University,
Private Bag 11 222, Palmerston North, New Zealand

Abstract

Lesions on cetacea can be useful to assess the natural and anthropogenic pressures faced by a population. The aim of this study was to assess the viability of photo-identification (photo-ID) as a tool to examine potential pressures affecting gregarious, free-ranging common dolphins (*Delphinus* sp.). Photo-ID was collected between 2010 and 2013 in the Hauraki Gulf (HG), New Zealand. From 1,411 independent encounters, 2,083 individuals were identified from permanent nicks and notches on their dorsal fins. Of these individuals, the number of lesions on 12 body sectors was assessed. Prevalence was determined by weighting the number of lesions by the cumulative number of images for each body sector. Of the 2,083 individuals identified, 77.9% ($n = 1,622$) exhibited lesions. Of all body segments examined, the anterior peduncle exhibited the highest percentage of lesions (91.1%). Most lesions observed were represented by indentations and impressions (84.2%, $n = 1,368$), followed by cut-like indentations (54.1%, $n = 878$), hyper-pigmented lesions (43.1%, $n = 700$), and hypo-pigmented lesions (37.4%, $n = 607$). A significant difference in the prevalence of lesions between the leading and trailing edges of dorsal fins was evident. Possible causes of lesions are discussed, including intra- or interspecific interactions, environmental conditions, infectious origins, fisheries and vessel interactions, and/or human-induced environmental stressors. Findings suggest that despite limitations, photo-ID can be used as an opportunistic, non-invasive research tool to examine lesions on free-ranging delphinids.

Key Words: photo-identification, anthropogenic impacts, physical injuries, wounds, epidermal conditions, delphinids

Introduction

A variety of dermal lesions have been observed on live, stranded, and bycaught cetaceans worldwide. Such lesions have been described as hyper-pigmented (Wilson et al., 1997, 1999; Bearzi et al., 2009; Frode, 2009; Burdett Hart et al., 2012), hypo-pigmented (Harzen & Brunnick, 1997; Wilson et al., 1997; Van Bressem et al., 2007; Bearzi et al., 2009), targetoid (Geraci et al., 1979; Thompson & Hammond, 1992; Burdett Hart, 2011), concentric rings (Froude, 2009), tattoo-like (Flom & Houk, 1979; Van Bressem et al., 1999a, 1999b, 2009c), yellow-orange discolouration (Riggin & Maldini, 2010; Burdett Hart, 2011; Burdett Hart et al., 2012), depressed and sunken (Baker, 1992; Van Bressem et al., 1999a, 1999b; Blanchard et al., 2001), and raised and proliferative (Baker, 1992; Rehtanz et al., 2006; Reif et al., 2006).

Detection of lesions can be useful to identify potential natural or anthropogenic pressures faced by cetaceans in the marine environment. Natural pressures may include intra- (Scott et al., 2005; Marley et al., 2013) or interspecific interactions (Steiger et al., 2008; Dwyer & Visser, 2011; Moore & Barco, 2013), environmental conditions (e.g., changes in water temperature and/or salinity; Harzen & Brunnick, 1997; Bertulli et al., 2012), and infections (Isidoro-Ayza et al., 2014; Lecis et al., 2014). In addition, anthropogenic pressures may include entanglement in fishing gear (Donaldson et al., 2010; Moore & Barco, 2013), vessel interactions (Dwyer et al., 2014; Luksenburg, 2014; Sierra et al., 2014), and human-induced environmental stressors (e.g., poor water quality and nutrient enrichment; Flom & Houk, 1979; Geraci et al., 1979). Through identifying the potential natural and/or anthropogenic pressures faced by free-ranging populations, inferences can be made concerning the impacts on a specific population.

While lesions identified via photo-ID in free-ranging populations have been reported (Van Bressem et al., 2007, 2015; Murdoch et al., 2008; Kiszka et al., 2009; Daura-Jorge & Simões-Lopes, 2011; Bertulli et al., 2012; Burdett Hart et al., 2012; Bessesen et al., 2014; Sanino et al., 2014), the literature is heavily biased towards coastal species that are observed in small group sizes, particularly common bottlenose dolphins (Thompson & Hammond, 1992; Wilson et al., 2000; Van Bressem et al., 2003, 2007; Rehtanz et al., 2006; Flach et al., 2008; Bearzi et al., 2009; Maldini et al., 2010; Melero et al., 2011). Considerably less is described in the literature for gregarious oceanic delphinids such as common dolphins (*Delphinus* sp.), with most records originating from strandings (Dixon, 1984; Reidarson et al., 1998; Van Bressem et al., 2001, 2007; Silva & Sequeira, 2003; Stockin et al., 2009) or fisheries bycatch (Van Bressem & Van Waerebeek, 1996; Van Bressem et al., 1996, 2001, 2006a, 2006b, 2009c; Duignan et al., 2003). No studies have been conducted using photo-ID to examine lesions on free-ranging oceanic populations of common dolphins, despite the natural (Van Bressem et al., 1999a, 2006b, 2007) and anthropogenic (Read & Murray, 2000; Ostman-Lind et al., 2004; Baird & Gorgone, 2005; Neumann & Orams, 2006; Courbis, 2007; Rowe, 2007; Campbell-Malone et al., 2008; Stockin et al., 2008a, 2008b, 2009; Stockin & Orams, 2009; Weir et al., 2010; Martinez & Stockin, 2013; Thompson et al., 2013; Kügler & Orbach, 2014) pressures faced by this species.

Common dolphins within the Hauraki Gulf (HG), New Zealand, form part of an open population which range along the northeastern coastline of the North Island (Stockin et al., 2014; Hupman, 2016). Despite this extensive range, the HG appears to be a stronghold for this species, with seasonal abundance ranging between 732 (CI = 460 to 1,177) in autumn 2010 to 5,304 (CI = 4,745 to 5,930) in spring 2013 (Hupman, 2016). An analysis of lesions affecting *Delphinus* within this region is, therefore, informative to identify and discuss the natural and anthropogenic pressures likely faced within the HG and potentially throughout New Zealand waters.

The aim of this study was to assess the viability of photo-ID as a tool to examine the prevalence of lesions on free-ranging common dolphins. Specifically, the objectives were (1) to apply a classification system to examine the prevalence of lesions on common dolphins within the HG and (2) to discuss potential natural and anthropogenic causes of such lesions. By examining the natural and anthropogenic pressures, scientists are able to determine potential threats to populations and manage such threats over time.

Methods

Field Methods

Data Collection—Non-systematic, dedicated photo-ID surveys were undertaken from January 2010 to December 2013 inclusive in the HG, New Zealand (36° 10' to 37° 10' S, 174° 40' to 175° 30' E). Observations were independently conducted from two vessel types: (1) *Aihe II*, a 5.5-m research vessel, fitted with a 120-hp four-stroke outboard engine; and (2) *Dolphin Explorer*, a 20-m commercial tour catamaran, powered by twin 350-hp inboard engines. Surveys were conducted in good visibility (≥ 1 km), swell (< 1 m), and Beaufort sea state (≤ 4) (Stockin et al., 2008b). Vessels conducted surveys both concurrently and independently. During surveys, vessels would approach the focal group to the rear in a continuous, slow (~ 5 kts) manoeuvre before travelling parallel to the group to conduct photo-ID (Stockin et al., 2008b).

Photographs were collected by a team of two to five trained observers (including the first author) concurrently, following standardised methods (Würsig & Jefferson, 1990). Multiple images were taken at a 90° angle (Würsig & Jefferson, 1990) when dolphins surfaced within 25 m of the platform (Tyne et al., 2014). Photo-ID was randomly collected for each dolphin in a group without bias towards marked or unmarked individuals (Würsig & Jefferson, 1990). Regardless of group size, an attempt was made to photo-ID as many dolphins within the group as possible. While photo-ID focused on capturing dorsal fins, other body sectors were also photographed extensively.

All images were graded according to photographic quality (PQ) with the aim of minimising bias in lesion identification and reducing misidentifications. Images were classified as (1) poor, (2) fair, (3) good, or (4) excellent quality (Hupman, 2016). Only fair, good, and excellent quality images were used for analysis.

Images were compared manually to identify unique individuals within the population (Tyne et al., 2014) and were deemed *marked* when they displayed permanent nicks and notches on the leading or trailing edge of the left side of the dorsal fin (Würsig & Würsig, 1977; Würsig & Jefferson, 1990). In addition to nicks and notches, pigmentation patterns were also used as a secondary feature to aid in individual recognition (Hupman, 2016). A threshold for distinctiveness was used to integrate distinctively marked individuals (DMIs) into the *Hauraki Gulf Common Dolphin Catalogue* (HGDCD). Each new prospective individual was carefully examined, and all matches were scrutinized by at least two experienced observers before being assigned a unique identification code.

Data Analysis

Analysis of Lesions—Only images of recognisable individuals within the HGCDC were included in this analysis to avoid false positive or negative errors. Regardless of which body sectors were present in each image, only photographs which displayed the dorsal fin were assessed to ensure each image could be assigned to an individual in the HGCDC. The number of images for each of the 12 predefined body segments (Figure 1) were noted for each individual. For dolphins photographed on multiple occasions, all images were screened for the presence/absence of a lesion over time. For example, if an individual exhibited no lesions on the first occasion but exhibited lesions on the second encounter, this individual was recorded as showing the presence of a lesion, regardless of the temporal variation. Likewise, if an individual exhibited a lesion on the first occasion but the lesion had healed on the second encounter, this dolphin was still recorded as showing the presence of a lesion.

Screening involved examining digital images with the naked eye using Adobe *Photoshop CS5* (Adobe Systems Incorporated, 2010) to identify which lesions were present/absent. Once a lesion was identified, it was assigned to the appropriate body sector (Scott et al., 2005; Marley et al., 2013; Figure 1), and the total number of lesions per body sector were noted.

Lesion Classification and Prevalence—A lesion was defined as any abnormality in the gross appearance of body tissue (Lane et al., 2008). For the purposes of the present study, physical injuries, wounds, skin lesions, and epidermal conditions were all considered as lesions. Lesions were classified into 12 categories according to descriptions developed for the present study and from gross morphology or images in the published literature (Table 1).

Where individuals had multiple lesion types, they were listed in all respective categories. Any lesion which could not be confidently classified was deemed inconclusive and removed from further analysis.

Lesions Per Body Sector—For each individual, the presence or absence of lesions on each body sector was given a binary weighting. When a sector contained one or multiple lesions, it was assigned a value of one. Sectors that did not contain lesions were given a value of zero. This value represented the number of individuals with a lesion.

Previous studies weighted each image by the percentage of an individual's body sector that was visible (Scott et al., 2005). For example, if more than 75% was visible, the image was weighted as "1" (entirely visible); and if less than 75% of a body sector was visible, the image was weighted as "0.5" (partially visible) (Scott et al., 2005). To improve precision further, the total number of individuals with images for each body sector (i.e., the denominator in the ratio used to determine a sector's prevalence of lesions) was calculated to account for sectors only partially visible in a photograph. This was determined by the proportion of the sector that was visible from all images of that individual. To illustrate, if a lesion was visible in an image, that image was scored as "1," indicating certainty that a lesion was present (regardless of the percentage of the body sector visible). However, if no lesion was visible, the individual was weighted by the proportion of the body sector that was visible. For example, if an individual had five images depicting the head, and these five images visibly encompassed 70% of the head, it was scored as 0.70. The weights of each sector were summed to determine the equivalent number of images for each body sector, referred to as the *cumulative number of images*. The prevalence of

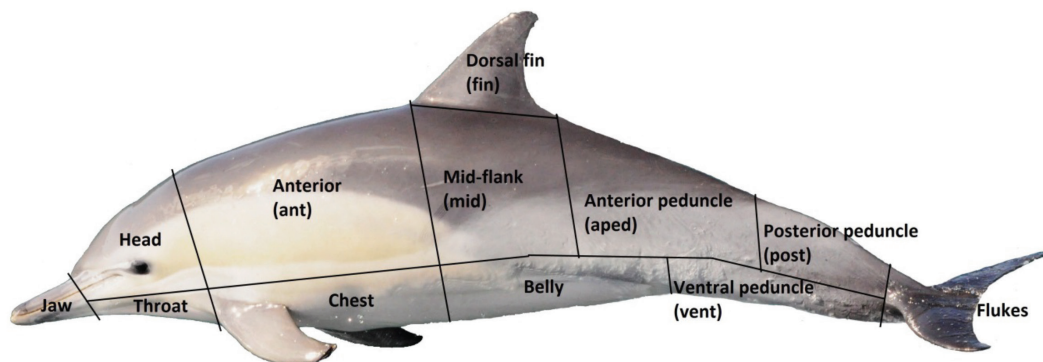

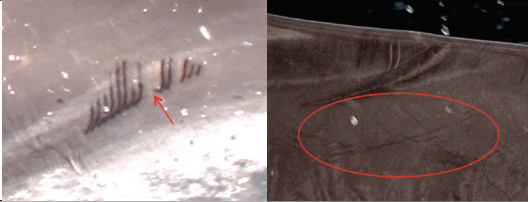












Figure 1. Common dolphin (*Delphinus* sp.) with the distinct body sectors for analysis of lesions (modified from Scott et al., 2005; Marley et al., 2013) defined

Table 1. Lesions on common dolphins (*Delphinus* sp.) photo-identified between January 2010 and December 2013 in the Hauraki Gulf (HG), New Zealand; ovals/arrows highlight areas with lesions (adapted from Flom & Houk, 1979; Bardale, 2011; Harrison, 2012; Moore & Barco, 2013; Luksenburg, 2014; Roe, unpub. data).

Category	Description	Image	
(1) Scars	Fibrous tissue, covered by epithelium, which can result from the healing of a wound. Subcategories include (i) unidentified scar and (ii) shark scar, which were either caused by (1) an unidentified shark (scar with deep and wide spaced tooth rakes or a crescent-shaped scar with or without tooth rakes) or (2) a cookie cutter shark (<i>Isistius</i> sp.) (small-, circular-, oval-, elliptic-, or conical-shaped scar).		
(2) Indentations and impressions*	(i) Indentations do break the surface of the epidermis, causing the development of fibrous tissue (and, therefore, includes scratches or rake marks); and (ii) impressions do not break the surface of the epidermis and usually occur from an object being wrapped around leading and/or trailing edges of a fin, flipper, or fluke.		
(3) Cut-like indentations**	Cut-like indentation (or laceration) resulting in a tear of the epidermis. Includes straight, curved, or semi-curved incisions, cuts, or slashes of variable lengths.		
(4) Full thickness wounds of the dorsal fin**	Wounds of the dorsal fin which extend deeper than the epidermis. Subcategories include (i) linear severed (cleanly severed/amputated part of the dorsal fin); (ii) non-linear severed/amputated part of the dorsal fin with irregular borders—the severed part is one notch being > 5% deep and situated towards the centre of the tip of the dorsal fin; and (iii) straight, deep cuts (v-shaped cut of the dorsal fin that is deeper horizontally than vertically).		
(5) Hyper-pigmented	Section of the epidermis that is darker than the surrounding skin without a light border. Lesions are flat, may be poorly or well-defined, and of any size. Subcategories include (i) hyper-pigmented, small, focal lesions (dark, circular, small lesions); and (ii) hyper-pigmented, large, clumped lesions (dark, clumped lesions of variable sizes).		

(6) Hypo-pigmented	Section of the epidermis that is lighter than the surrounding skin and does not have dark border/bands of hypo-pigmentation. Lesions are flat, may be poorly defined, and of any size.	
(7) Targetoid	Small (< 3 cm), circular, oval, or irregular lesions, with dark- or light-fringed borders, either flat or slightly raised. Subcategories include (i) targetoid, light-fringed (light-fringed border); and (ii) targetoid, dark-fringed (dark-fringed border).	
(8) Concentric rings	Lesions with a circular, scalloped edge of alternating concentric bands of hyper- and hypo-pigmentation with a black punctiform centre	
(9) Tattoo-like	Well-defined lesions with “the appearance of a tattoo,” which can be slightly depressed and reach > 10 cm in size	
(10) Yellow/orange discolouration	Abnormal yellow/orange discolouration of the epidermis where the skin remains intact	
(11) Depressed and sunken	Depressed or sunken lesions, which may include ulcers, erosions, and healed, contracted scars	
(12) Raised and proliferative	Raised lesions, which can include lesions that are nodular/vesicular, multinodular, or plaques	

*Indentations and impressions were grouped as one category due to the difficulty of determining via photo-ID whether the epidermis was broken.

**Represents categories which only relate to the dorsal fin.

lesions for each body sector was further calculated by dividing the number of individuals with a lesion by the cumulative number of images for each body sector. This number, given as a percentage, represented the *lesion ratio*.

Dorsal Fin Lesions—Only individuals which were marked (i.e., exhibiting nicks or notches) were able to be catalogued. For all catalogued individuals, we assessed if there was a difference in the prevalence and/or depth of the nicks and notches on the leading and trailing edges of the dorsal fin.

For the purposes of this study, nicks and notches on the leading edge of the dorsal fin were considered as cut-like indentations regardless of their size. This is due to the sturdy structure of the leading edge resulting in an increased likelihood that such a lesion is a result of anthropogenic activities (Read & Murray, 2000). However, nicks and notches on the trailing edge were only considered as cut-like indentations when they were > 5% deep since such cuts are likely a consequence of conspecific natural behaviour (Kügler & Orbach, 2014).

Nicks and notches were measured (both vertically and horizontally) using *ImageJ*, Version 1.48 (Abramoff et al., 2004). Herein, the relative depth of the nick/notch was determined by dividing the depth of the nick/notch by the total length of the base of the dorsal fin (as measured on an image; Luksenburg, 2014). The length of the dorsal base was measured between the anterior and posterior insertions of the dorsal fin (Luksenburg, 2014). Nicks and notches were categorised as occurring on the leading, trailing, or both edges and were classified as $\leq 5\%$, 5 to 10%, or $\geq 10\%$ deep. A Fisher's exact test was conducted to determine if there was a significant difference in the prevalence of nicks and notches between the leading and trailing edges.

Results

A total of 233,624 images were taken between January 2010 and December 2013. Of these, 30,918 images from 1,411 independent encounters were used for analysis. This resulted in a total of 2,083 unique individuals being catalogued (Table 2).

Of the 2,083 individuals, 1.1% ($n = 23$) displayed a lesion for which classification was inconclusive. Lesions were observed on 77.9% ($n = 1,622$) of individuals, with each individual exhibiting between one and ten types of lesions (Table 3).

Most lesions observed were represented by indentations and impressions (84.2%, $n = 1,368$), followed by cut-like indentations (54.1%, $n = 878$), hyper-pigmented lesions (43.1%, $n = 700$),

and hypo-pigmented lesions (37.4%, $n = 607$) (Table 4). Raised/proliferative lesions were the least observed (0.3%, $n = 5$) (Table 4).

The highest (91.1%, $n = 1,118$) and lowest (7.1%, $n = 2$) percentage of lesions were observed on the anterior peduncle and the throat, respectively (Table 5). A total of 82.7% of individuals ($n = 1,336$) exhibited lesions on dorsal fins (Table 5). No lesions were observed on the flukes (Table 5).

Individuals exhibited nicks and notches of various sizes on both the leading and trailing edges (Figure 2), with a significant difference in prevalence between edges detected (Fisher's exact test; $p = 0.01$; Figure 2).

Table 2. Summary of photo-ID effort and results for common dolphins (*Delphinus* sp.) conducted between January 2010 and December 2013 in the HG, New Zealand

Year	# photo-ID surveys	Groups encountered	Total individuals identified
2010	43	88	141
2011	73	232	274
2012	140	450	574
2013	163	641	1,094
Total	419	1,411	2,083

Table 3. Numbers of lesions found on individual common dolphins (*Delphinus* sp.) ($n = 2,083$) between January 2010 and December 2013 in the HG, New Zealand; the number of times lesions were not detected is represented in *italics*. The total is summed only for individuals with 1 to 10 lesions (displayed in **bold**) to exclude individuals with no lesions detected.

# lesions	Individuals <i>n</i> (%)
0	<i>461 (22.1)</i>
1	449 (21.6)
2	400 (19.2)
3	253 (12.1)
4	201 (9.6)
5	160 (7.7)
6	93 (4.5)
7	41 (2.0)
8	19 (0.9)
9	5 (0.2)
10	1 (0.0)
Total (1-10)	1,622 (77.9)

Table 4. Types and subtypes of lesions (totals in bold) found on individual common dolphins (*Delphinus* sp.) observed between January 2010 and December 2013 in the HG, New Zealand; the total number of individuals with lesions and/or deformities was 1,624. **Note:** Individuals may be included in multiple categories.

Type	Subtype	Individuals <i>n</i> (%)
(1) Scars	Unidentified scar	198 (12.2)
	Shark scar	5 (0.3)
		203 (12.5)
(2) Indentations and impressions	--	1,368 (84.2)
(3) Cut-like indentations	--	878 (54.1)
(4) Full thickness wounds of the dorsal fin	Linear, severed dorsal fin	50 (3.1)
	Non-linear, severed dorsal fin	46 (2.8)
	Straight, deep cut	17 (1.0)
		113 (7.0)
(5) Hyper-pigmented	Small, focal lesions	251 (15.5)
	Large, clumped lesions	449 (27.6)
		700 (43.1)
(6) Hypo-pigmented	--	607 (37.4)
(7) Targetoid	White-fringed	322 (19.8)
	Black-fringed	133 (8.2)
		455 (28.0)
(8) Concentric rings	--	58 (3.6)
(9) Tattoo-like	--	31 (1.9)
(10) Yellow/orange discolouration	--	214 (13.2)
(11) Depressed/sunken	--	6 (0.4)
(12) Raised/proliferative	--	5 (0.3)

Discussion

This study aimed to assess the viability of photo-ID as a non-invasive tool to examine the prevalence of lesions on free-ranging gregarious delphinids. Herein, photo-ID was applied for the first time to assess common dolphin lesion prevalence. Through this examination, we were able to identify potential natural and anthropogenic

pressures which may have affected this free-ranging, gregarious delphinid. This study highlighted that photo-ID is a viable tool (1) to examine the prevalence of lesions on free-ranging, gregarious delphinids and (2) to provide first insight into the natural and anthropogenic pressures affecting such populations.

Prevalence of Lesions

The prevalence of lesions for common dolphins identified within the HG ($n = 2,083$) was high (77.9%, $n = 1,622$). Comparisons to other worldwide populations of free-ranging delphinids was impossible since all other studies of this species within the literature report only from *postmortem* observations. However, in a more comparable study of Taiwanese humpback dolphins (*Sousa chinensis taiwanensis*), 37.1% of individuals exhibited lesions which were likely caused by local environmental factors (e.g., water quality, temperature, and salinity) and anthropogenic impacts (Yang et al., 2013). Prevalence of lesions in free-ranging bottlenose dolphins has been reported between 38% in the northwest Atlantic (Burdett Hart et al., 2012) to 100% in Cornwall, England (Wilson et al., 1999). For these aforementioned populations, factors, including seasonal or environmental fluctuations, disease and infections, vitamin deficiencies, parasites, anthropogenic pollutants, diatom growth, ultraviolet radiation, habitat degradation, and pollution, were suggested as possible causes. As 77.9% of catalogued common dolphins examined within the HG exhibited various forms of lesions, this prevalence is comparable to the coastal populations of cetaceans described previously.

Of all categories of lesions observed in this study, the highest prevalence was represented by indentations and impressions (84.2%, $n = 1,368$). To the contrary, 3.3% of Atlantic spotted dolphins (*Stenella frontalis*) in the southern Caribbean exhibited indentations (Luksenburg, 2014). However, large variation in prevalence is likely due to the inclusion of rake marks within the indentation and impression category for the present study; whereas Luksenburg (2014) categorised rake marks separately from all other lesions. In the present study, rake marks were often too problematic to reliably differentiate from other impressions. This was primarily due to the difficulty in determining lesion depth into the epidermis (i.e., whether the epidermis was broken) from photo-ID data alone. Therefore, a conservative approach was implemented by classifying any form of impression or indentation into a pooled category.

Table 5. Number of individuals with lesions, the cumulative number of images, and the lesion ratio for each body sector of common dolphins (*Delphinus* sp.) ($n = 2,083$) photographed between January 2010 and December 2013 in the HG, New Zealand. The lesion ratio was calculated by dividing the number of individuals with a lesion by the cumulative number of images for each body sector.

Body sector	# individuals with lesions	# cumulative images of body sector	Lesion ratio (%)
Jaw	18	86.7	20.8
Head	81	230.6	35.1
Throat	2	28.4	7.1
Anterior	837	1,006.2	83.2
Chest	17	37.4	45.5
Dorsal fin	1,336	1,615.8	82.7
Mid-flank	899	1,153.0	78.0
Belly	93	169.8	54.8
Anterior peduncle	1,118	1,226.6	91.1
Ventral peduncle	71	110.8	64.1
Posterior peduncle	592	676.0	87.6
Flukes	0	10.7	0.0

Potential Natural and Anthropogenic Pressures Identified via Photo-ID

Inter- and intraspecific interactions have been reported for a number of cetaceans (Scott et al., 2005; Steiger et al., 2008; Dwyer & Visser, 2011; Marley et al., 2013). Considering the social nature of *Delphinus* (Bruno et al., 2004; Hupman, 2016), inter- and intraspecific interactions are a likely natural pressure affecting common dolphins within the HG. Common dolphins have been reported to conduct aggressive behaviours, some of which have caused wounds on conspecifics (Neumann, 2001). Interspecific interactions may also occur within the HG as bottlenose dolphins are regularly encountered within this region (Berghan et al., 2008; Dwyer et al., 2014) and have been previously reported as aggressive to other delphinids worldwide (Jepson & Baker, 1998; Barnett et al., 2009). Likewise, interactions with unidentified sharks and/or cookie cutter sharks (*Isistius* sp.) are reported herein. This is expected considering the many shark species reported as predators of common dolphins within New Zealand waters (Stockin et al., 2008b) and considering the number of shark species which inhabit the HG (Francis & Ó Maolagáin, 2000; Kendrick & Francis, 2002; Francis, in press).

Environmental conditions, such as fluctuations in water temperature, are another natural pressure which can affect cetaceans (Burdett Hart et al., 2012). As common dolphins occur at temperatures ranging between 12.0 and 25.6° C in the HG

(Stockin et al., 2008b), it is possible that fluctuations in temperature could be a cause of lesions on common dolphins within this region. Likewise, pressure can be placed on cetacean populations by infectious origins which may be caused by impaired immune systems (Harzen & Brunnick, 1997; Reif et al., 2009), vitamin deficiencies (Manton, 1975), reactions to parasites (Fraser & Mays, 1986), diatom growth (Denys, 1997), excessive exposure to ultraviolet radiation (Geraci et al., 1986), and jaundice (Fraser & Mays, 1986). While such origins cannot be confirmed to affect common dolphins within the HG, they remain possible causes of lesions identified in this study.

Fishing interactions have been identified as an anthropogenic pressure affecting many cetacean populations worldwide (Jefferson & Curry, 1994; Kuiken et al., 1994; Kirkwood et al., 1997; Donaldson et al., 2010). The greatest fisheries pressure to common dolphins in New Zealand waters is midwater trawling, a fishing method used to capture jack mackerel (*Trachurus* spp.) off the west coast of the North Island (Du Fresne et al., 2007; Rowe, 2007; Stockin & Orams, 2009; Thompson et al., 2013). While common dolphins are the most frequently bycaught cetacean in the New Zealand commercial trawl fisheries (Thompson et al., 2013), no studies have examined the effects of fishing operations in the HG. Despite this, a previous study examining mortality of common dolphins between 1998 and 2008 in New Zealand waters reported 28% of individuals

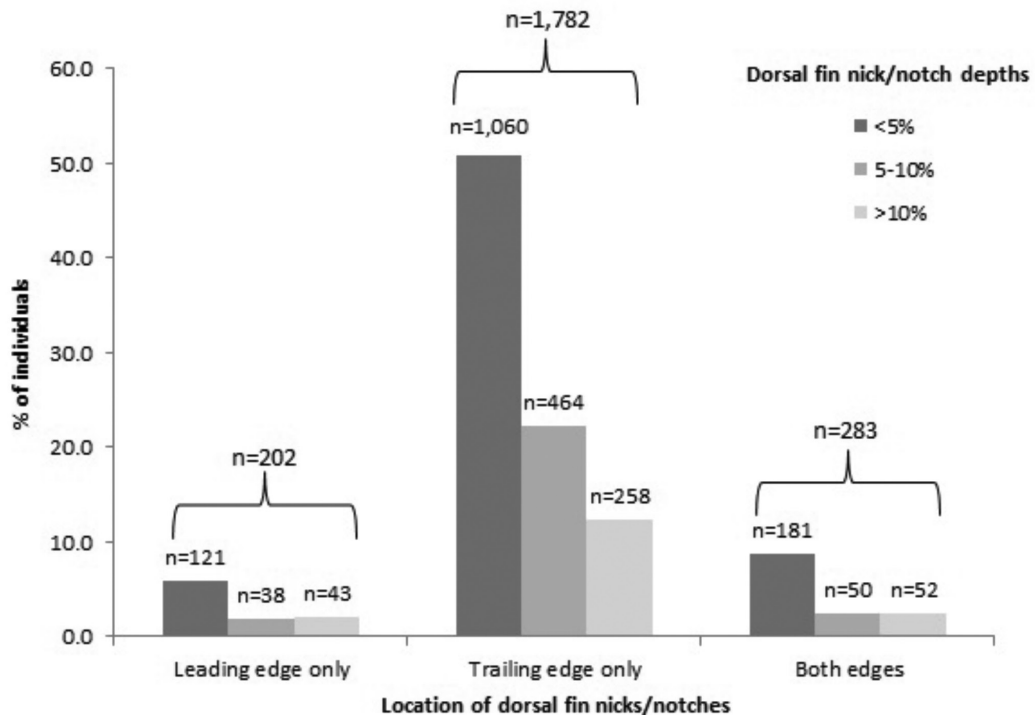


Figure 2. Percentage of common dolphin (*Delphinus* sp.) individuals exhibiting dorsal fin nicks/notches of different depths (< 5%, 5 to 10%, and > 10%; nick/notch depth is a percentage of the base of the fin) and on different parts of the dorsal fin between January 2010 and December 2013 in the HG, New Zealand

exhibited evidence of set net entanglement of which some individuals were recorded within the HG (Stockin et al., 2009). This indicates that fishing interactions have previously occurred in the HG and may continue to affect *Delphinus* populations in this region.

Vessel interactions are another anthropogenic pressure within the marine environment (Baird & Gorgone, 2005; Van Waerebeek et al., 2007). Such interactions can cause infection following such trauma (Kompanje, 1995). Records of injuries and mortality caused by vessel interactions have been previously reported in the HG for bottlenose dolphins (Dwyer et al., 2014) and Bryde's whales (*Balaenoptera edeni/brydei*; Stockin et al., 2008c; Constantine et al., 2015), and indeed for common dolphins (Stockin et al., 2008b; Martinez & Stockin, 2013). Such vessel interactions in the HG are to be expected considering that common dolphins occupy relatively shallow waters (7 to 52 m; Stockin et al., 2008b) and the high level of marine traffic within this region (Stockin et al., 2009; Bassett et al., 2016).

Human-induced environmental stressors (e.g., poor water quality, inadequate water filtration, and/or environmental contaminants) are known to cause increased stress levels (Geraci et al., 1979; Johnson & McCrea, 1992; Fair & Becker, 2000; Wright et al., 2008) and the promotion of infections (Murdoch et al., 2008; Van Bressem et al., 2009a, 2009b; Bessezen et al., 2014) in cetacean populations. Within the HG, water quality has been affected by increased nutrient loads through wastewater discharges, fertiliser application, and livestock effluent (The Hauraki Gulf Forum, 2014). Nitrogen loads in this region are among the highest in New Zealand as the highest amount of livestock per ha is found within the Hauraki Plains (The Hauraki Gulf Forum, 2014). While the full effects of human-induced environmental stressors in the HG remain unknown, it is possible that they affect common dolphins in this region.

Limitations

While photo-ID is a useful non-invasive technique to investigate the prevalence of lesions, this

methodology limited certainty of aetiology from photographic data alone. For example, one limitation was that rake marks (a form of indentation) were often too unreliable to confidently differentiate from any other form of impression based on photo-ID data alone. This resulted in the pooling of data and the overinflation of indentations reported due to the inclusion of rake marks.

Another limitation was the use of photo-ID to identify individual animals, which may have over- or underestimated the prevalence of lesions within the HG population. For example, to avoid pseudoreplication, only marked individuals were included in the analysis. As some dorsal fin marks are also considered lesions, this would have resulted in an overestimate in lesion prevalence. In contrast, the use of photo-ID may have resulted in an underestimation of the prevalence of lesions found on common dolphins in the HG. This is because photo-ID primarily only captures images of a small proportion of the individual (focused on the dorsum) and is not always able to identify all individuals present within a population, particularly in the HG. Indeed, this population is transient in nature, with only a third of the individuals catalogued sighted more than once (Hupman, 2016). While lesion prevalence was summed over the entire sighting history for each animal, individuals that were not resighted may have had a lower prevalence of lesions. Therefore, the more an individual was resighted, the more chance researchers had to identify a lesion.

Previous studies have indicated differences in susceptibility and severity of lesions of varying age classes (Van Bressem et al., 2003; Maldini et al., 2010) and gender (Rowe et al., 2010; Van Bressem et al., 2012). However, unfortunately, the prevalence of lesions was not assessed for different age classes or gender in this study since only marked adults appear in the HG CDC. While the prevalence of lesions on different body regions was examined, this analysis may also be biased considering that individuals exhibiting lesions in one body section may not be independent of other regions of the body.

Conclusion

Photo-ID can be used as an opportunistic, non-invasive research tool to examine lesions on gregarious oceanic species. Furthermore, such a method can be valuable to examine potential pressures affecting free-ranging species, although this is not without limitation. The examination of lesions on free-ranging common dolphins within this region highlighted potential natural and anthropogenic effects, including intra- or interspecific interactions, environmental conditions, infectious origins, fisheries and vessel interactions, and

human-induced environmental stressors. Future studies should be conducted across different temporal and spatial scales and assess variability across different age classes.

Acknowledgments

This project was funded by the Department of Conservation (DOC), the Freemasons Society, and the New Zealand Federation of Graduate Women. Krista Hupman was a recipient of a Massey University Doctoral Scholarship and received additional financial support from the Institute of Natural and Mathematical Sciences, Massey University. We thank the crew and management of Auckland Whale and Dolphin Safaris for access to their vessel and for their ongoing support and assistance. Special thanks to Sarah Dwyer who provided additional common dolphin photos from the Hauraki Gulf. Thanks also to the Coastal-Marine Research Group at Massey University, the New Zealand Common Dolphin Project, and especially to all the research interns who assisted with data collection and photo-identification analysis. We also thank Lisa-Marie Harrison and Jolanda Luksenburg for their advice on lesion classification systems, and Micah Brodsky for his initial advice on lesion description criteria.

Literature Cited

- Abramoff, M. D., Magalhaes, P. J., & Ram, S. J. (2004). Image processing with *ImageJ*. *Biophotonics International*, 11, 36-42.
- Adobe Systems Incorporated. (2010). *Adobe Photoshop CS5*. New York: Adobe Systems Incorporated.
- Baird, R. W., & Gorgone, A. M. (2005). False killer whale dorsal fin disfigurements as a possible indicator of long-line fishery interactions in Hawaiian waters. *Pacific Science*, 59, 593-601. <https://doi.org/10.1353/psc.2005.0042>
- Baker, J. R. (1992). Skin disease in wild cetaceans from British waters. *Aquatic Mammals*, 18(1), 27-32.
- Bardale, R. (2011). *Principles of forensic medicine and toxicology*. New Delhi, India: Jaypee Brothers Medical Publishers. <https://doi.org/10.5005/jp/books/11334>
- Barnett, J., Davison, N., Deaville, R., Monies, R., Loveridge, J., Tregenza, N., & Jepson, P. D. (2009). Postmortem evidence of interactions of bottlenose dolphins (*Tursiops truncatus*) with other dolphin species in south-west England. *Veterinary Record*, 165, 441-444. <https://doi.org/10.1136/vr.165.15.441>
- Bassett, I. E., Cook, J., Buchanan, F., & Russell, J. S. (2016). Treasure islands: Biosecurity in the Hauraki Gulf Marine Park. *New Zealand Journal of Ecology*, 40, 1-17. <https://doi.org/10.20417/nzjecol.40.28>
- Bearzi, M., Rapoport, S., Chau, J., & Saylan, C. (2009). Skin lesions and physical deformities of coastal and off-

- shore common bottlenose dolphins (*Tursiops truncatus*) in Santa Monica Bay and adjacent areas, California. *Ambio*, 38, 66-71. <https://doi.org/10.1579/0044-7447-38.2.66>
- Berghan, J., Algie, K. D., Stockin, K. A., Wiseman, N., Constantine, R., Tezanos-Pinto, G., & Mourão, F. (2008). A preliminary photo-identification study of bottlenose dolphins (*Tursiops truncatus*) in Hauraki Gulf, New Zealand. *New Zealand Journal of Marine and Freshwater Research*, 42, 465-472. <https://doi.org/10.1080/00288330809509974>
- Bertulli, C., Cecchetti, A., Van Bresseem, M., & Van Waerebeek, K. (2012). Skin disorders in common minke whales and white-beaked dolphins off Iceland: A photographic assessment. *Journal of Marine Animals and Their Ecology*, 5, 29-40.
- Bessesen, B. L., Oviedo, L., Hart, L. B., Herra-Miranda, D., Pacheco-Polanco, J. D., Baker, L., . . . Acevedo-Gutiérrez, A. (2014). Lacaziosis-like disease among bottlenose dolphins *Tursiops truncatus* photographed in Golfo Dulce, Costa Rica. *Diseases of Aquatic Organisms*, 107, 173-180. <https://doi.org/10.3354/dao02692>
- Blanchard, T. W., Santiago, N. T., Lipscomb, T. P., Garber, R. L., McFee, W. E., & Knowles, S. (2001). Two novel alphaherpesviruses associated with fatal disseminated infections in Atlantic bottlenose dolphins. *Journal of Wildlife Diseases*, 37, 297-305. <https://doi.org/10.7589/0090-3558-37.2.297>
- Bruno, S., Politi, E., & Bearzi, G. (2004). *Social organisation of a common dolphin community in the eastern Ionian Sea: Evidence of a fluid fission-fusion society*. Proceedings of the Fifteenth Annual Meeting of the European Cetacean Society, Rome, Italy.
- Burdett Hart, L. (2011). *The use of longitudinal and cross-sectional photographic data to study skin disease in wild bottlenose dolphins (Tursiops truncatus)* (Doctoral dissertation). Medical University of South Carolina, Charleston.
- Burdett Hart, L., Rotstein, D. S., Wells, R. S., Allen, J., Barleycorn, A., Balmer, B. C., . . . Schwacke, L. H. (2012). Skin lesions on common bottlenose dolphins (*Tursiops truncatus*) from three sites in the north-west Atlantic, USA. *PLOS ONE*, 7, 1-12. <https://doi.org/10.1371/journal.pone.0033081>
- Campbell-Malone, R., Barco, S. G., Daoust, P., Knowlton, A. R., McLellan, W. A., Rotstein, D. S., & Moore, M. J. (2008). Gross and histologic evidence of sharp and blunt trauma in North Atlantic right whales (*Eubalaena glacialis*) killed by vessels. *Journal of Zoo and Wildlife Medicine*, 39, 37-55. <https://doi.org/10.1638/2006-0057.1>
- Constantine, R., Johnson, M., Riekkola, L., Jervis, S., Kozmian-Ledward, L., Dennis, T., . . . Aguilar de Soto, N. (2015). Mitigation of vessel-strike mortality of endangered Bryde's whales in the Hauraki Gulf, New Zealand. *Biological Conservation*, 186, 149-157. <https://doi.org/10.1016/j.biocon.2015.03.008>
- Courbis, S. (2007). Effect of spinner dolphin presence on level of swimmer and vessel activity in Hawai'ian bays. *Tourism in Marine Environments*, 4, 1-13. <https://doi.org/10.3727/154427307784835697>
- Daura-Jorge, F. G., & Simões-Lopes, P. C. (2011). Lobomycosis-like disease in wild bottlenose dolphins *Tursiops truncatus* of Laguna, southern Brazil: Monitoring of a progressive case. *Diseases of Aquatic Organisms*, 93, 163-170. <https://doi.org/10.3354/dao02291>
- Denys, L. (1997). Morphology and taxonomy of epizootic diatoms (*Epiphallina* and *Tursiocola*) on a sperm whale (*Physeter macrocephalus*) stranded on the coast of Belgium. *Diatom Research*, 12, 1-18. <https://doi.org/10.1080/0269249X.1997.9705398>
- Dixon, J. M. (1984). Hepatitis and bone lesions in a stranded juvenile common dolphin *Delphinus delphis* Linnaeus. *Australian Mammalogy*, 7, 225-228.
- Donaldson, R., Finn, H., & Calver, M. (2010). Illegal feeding increases risk of boat-strike and entanglement in bottlenose dolphins in Perth, Western Australia. *Pacific Conservation Biology*, 16, 157-161. <https://doi.org/10.1071/PC100157>
- Du Fresne, S. P., Grant, A. R., Norden, W. S., & Pierre, J. P. (2007). *Factors affecting cetacean bycatch in a New Zealand trawl fishery* (Department of Conservation Research and Development Series 282). Wellington: New Zealand Department of Conservation.
- Duignan, P. J., Gibbs, N. J., & Jones, G. W. (2003). *Autopsy of cetaceans incidentally caught in commercial fisheries, and all beachcast specimens of Hector's dolphins, 2001/02* (Department of Conservation Science Internal Series 119). Wellington: New Zealand Department of Conservation.
- Dwyer, S. L., & Visser, I. N. (2011). Cookie cutter shark (*Isistius* sp.) bites on cetaceans, with particular reference to killer whales (Orca) (*Orcinus orca*). *Aquatic Mammals*, 37(2), 111-138. <https://doi.org/10.1578/AM.37.2.2011.111>
- Dwyer, S., Kozmian-Ledward, L., & Stockin, K. A. (2014). Short-term survival of severe propeller strike injuries and observations on wound progression in a bottlenose dolphin. *New Zealand Journal of Marine and Freshwater Research*, 48, 294-302. <https://doi.org/10.1080/00288330.2013.866578>
- Fair, P. A., & Becker, P. R. (2000). Review of stress in marine mammals. *Journal of Aquatic Ecosystem Stress and Recovery*, 7, 335-354. <https://doi.org/10.1023/A:1009968113079>
- Flach, L., Van Bresseem, M. F., Reyes, J. C., Echegaray, M., Siciliano, S., Santos, M., . . . Van Waerebeek, K. (2008). Miscellaneous skin lesions of unknown aetiology in cetaceans from South America. *Report of the 60th Scientific Committee of the International Whaling Commission* (SC/60/DW4).
- Flom, J., & Houk, E. (1979). Morphologic evidence of pox-virus in "tattoo" lesions from captive bottlenosed dolphins. *Journal of Wildlife Diseases*, 15, 593-596. <https://doi.org/10.7589/0090-3558-15.4.593>

- Francis, M. P. (In press). Distribution, habitat and movement of juvenile smooth hammerhead sharks (*Sphyrna zygaena*) in northern New Zealand. *New Zealand Journal of Marine and Freshwater Research*. <https://doi.org/10.1080/00288330.2016.1171244>
- Francis, M. P., & Ó Maolagáin, C. (2000). Age, growth and maturity of a New Zealand endemic shark (*Mustelus lenticulatus*) estimated from vertebral bands. *New Zealand Journal of Marine and Freshwater Research*, 51, 35-42. <https://doi.org/10.1071/MF99012>.
- Fraser, C. M., & Mays, A. (1986). Management, husbandry, and diseases of marine mammals. In C. M. Fraser & A. Mays (Eds.), *The Merck veterinary manual* (6th ed., pp. 969-978). Kenilworth, NJ: Merck and Co Inc.
- Froude, M. (2009). *Epidermal disease in the Bunbury, Western Australia, population of bottlenose dolphins (Tursiops truncatus)* (Unpub. master's dissertation). University of Southampton, Southampton, UK.
- Geraci, J. R., Hicks, B. D., & St. Aubin, D. J. (1979). Dolphin pox: A skin disease of cetaceans. *Canadian Journal of Comparative Medicine*, 43, 399-404.
- Geraci, J. R., St. Aubin, D. J., & Hicks, B. D. (1986). Anatomy and physiology. The epidermis of odontocetes: A view from within. In M. M. Bryden & R. Harrison (Eds.), *Research on dolphins* (pp. 3-21). Oxford, UK: Clarendon Press.
- The Hauraki Gulf Forum. (2014). *State of our gulf 2014*. Auckland, New Zealand: The Hauraki Gulf Forum. Retrieved from www.aucklandcouncil.govt.nz/EN/environmentwaste/naturalenvironment/Documents/stateofourgulf2014.pdf
- Harrison, L. (2012). *A standardised method for the comparison of skin lesions among bottlenose dolphin populations in coastal areas* (Unpub. master's dissertation). Murdoch University, Perth, Australia.
- Harzen, S., & Brunnick, B. J. (1997). Skin disorders in bottlenose dolphins (*Tursiops truncatus*), resident in the Sado Estuary, Portugal. *Aquatic Mammals*, 23(1), 59-68.
- Hupman, K. (2016). *Photo-identification and its application to gregarious dolphins: Common dolphins (Delphinus sp.) in the Hauraki Gulf, New Zealand* (Doctoral dissertation). Massey University, Wellington, New Zealand. Retrieved from www.coastalmarineresearchgroup.com/PDFs/Final%20Hupman%20Thesis%2026022016.pdf
- Isidoro-Ayza, M., Ruiz-Villalobos, N., Pérez, L., Guzmán-Verri, C., Muñoz, P. M., Alegre, F., . . . Domingo, M. (2014). *Brucella ceti* infection in dolphins from the western Mediterranean sea. *BMC Veterinary Research*, 10, 206. <https://doi.org/10.1186/s12917-014-0206-7>
- Jefferson, T. A., & Curry, B. E. (1994). A global review of porpoise (Cetacea: Phocoenidae) mortality in gillnets. *Biological Conservation*, 67(2), 167-183. [https://doi.org/10.1016/0006-3207\(94\)90363-8](https://doi.org/10.1016/0006-3207(94)90363-8)
- Jepson, P. D., & Baker, J. R. (1998). Bottlenosed dolphins (*Tursiops truncatus*) as a possible cause of acute traumatic injuries in porpoises (*Phocoena phocoena*). *The Veterinary Record*, 143, 614-615. <https://doi.org/10.1136/vr.143.22.614>
- Johnston, P., & McCrea, I. (1992). *Death in small doses: The effects of organochlorines on aquatic ecosystems*. Amsterdam, The Netherlands: Greenpeace International.
- Kendrick, T. H., & Francis, M. P. (2002). Fish assemblages in the Hauraki Gulf, New Zealand. *New Zealand Journal of Marine and Freshwater Research*, 36, 699-717. <https://doi.org/10.1080/00288330.2002.9517124>
- Kirkwood, J. K., Bennett, P. M., Jepson, P. D., Kuiken, T., Simpson, V. R., & Baker, J. R. (1997). Entanglement in fishing gear and other causes of death in cetaceans stranded on the coasts of England and Wales. *The Veterinary Record*, 141, 94-98. <https://doi.org/10.1136/vr.141.4.94>
- Kiszka, J., Van Bresse, M. F., & Pusineri, C. (2009). Lobomycosis-like disease and other skin conditions in Indo-Pacific bottlenose dolphins *Tursiops aduncus* from the Indian Ocean. *Diseases of Aquatic Organisms*, 84, 151-157. <https://doi.org/10.3354/dao02037>
- Kompanje, E. J. O. (1995). Differences between spondylo-osteomyelitis and spondylitis deformans in small odontocetes based on museum material. *Aquatic Mammals*, 21(3), 199-203.
- Kügler, A., & Orbach, D. N. (2014). Sources of notch and scar patterns on the dorsal fins of dusky dolphins (*Lagenorhynchus obscurus*). *Aquatic Mammals*, 40(3), 260-273. <https://doi.org/10.1578/AM.40.3.2014.260>
- Kuiken, T., Simpson, V. R., Allchin, C. R., Bennett, P. M., Codd, G. A., Harris, E. A., . . . Phillips, S. (1994). Mass mortality of common dolphins (*Delphinus delphis*) in south west England due to incidental capture in fishing gear. *The Veterinary Record*, 134, 81-89. <https://doi.org/10.1136/vr.134.4.81>
- Lane, D., Guthrie, S., & Griffith, S. (2008). *Dictionary of veterinary nursing* (3rd ed.). Edinburgh: Elsevier/ Butterworth Heinemann.
- Lecis, R., Tocchetti, M., Rotta, A., Naitana, S., Ganges, L., Pittau, M., & Alberti, A. (2014). First gammaherpesvirus detection in a free-living Mediterranean bottlenose dolphin. *Journal of Zoo and Wildlife Medicine*, 45, 922-925. <https://doi.org/10.1638/2014-0019.1>
- Luksenburg, J. (2014). Prevalence of external injuries in small cetaceans in Aruban waters, southern Caribbean. *PLOS ONE*, 9, e88988. <https://doi.org/10.1371/journal.pone.0088988>
- Maldini, D., Riggan, J., Cecchetti, A., & Cotter, M. P. (2010). Prevalence of epidermal conditions in California coastal bottlenose dolphins (*Tursiops truncatus*) in Monterey Bay. *Ambio*, 39, 455-462. <https://doi.org/10.1007/s13280-010-0066-8>
- Manton, V. J. A. (1975). Vitamin requirements of dolphins. *Aquatic Mammals*, 3(1), 1-4.
- Marley, S. A., Cheney, B., & Thompson, P. M. (2013). Using tooth rakes to monitor population and sex differences in aggressive behaviour in bottlenose dolphins (*Tursiops truncatus*). *Aquatic Mammals*, 39(2), 107-115. <https://doi.org/10.1578/AM.39.2.2013.107>
- Martinez, E., & Stockin, K. A. (2013). Blunt trauma observed in a common dolphin *Delphinus* sp. likely

- caused by a vessel collision in the Hauraki Gulf, New Zealand. *Pacific Conservation Biology*, 19, 19-27. <https://doi.org/10.1071/PC130019>
- Melero, M., Rubio-Guerri, C., Crespo, J. L., Arbelo, M., Vela, A. I., García-Párraga, D., . . . Sánchez-Vizcaíno, J. M. (2011). First case of erysipelas in a free-ranging bottlenose dolphin (*Tursiops truncatus*) stranded in the Mediterranean Sea. *Diseases of Aquatic Organisms*, 97, 167-170. <https://doi.org/10.3354/dao02412>
- Moore, K., & Barco, S. (2013). *Handbook for recognizing, evaluating, and documenting human interaction in stranded cetaceans and pinnipeds* (NOAA Technical Memo NMFS-SWFSC-510). Washington, DC: National Oceanic and Atmospheric Administration.
- Murdoch, M. E., Reif, J. S., Mazzoil, M., McCulloch, S. D., Fair, P. A., & Bossart, G. D. (2008). Lobomycosis in bottlenose dolphins (*Tursiops truncatus*) from the Indian River Lagoon, Florida: Estimation of prevalence, temporal trends, and spatial distribution. *EcoHealth*, 5, 289-297. <https://doi.org/10.1007/s10393-008-0187-8>
- Neumann, D. R. (2001). The activity budget of free-ranging common dolphins (*Delphinus delphis*) in the northwestern Bay of Plenty, New Zealand. *Aquatic Mammals*, 27(2), 121-136.
- Neumann, D. R., & Orams, M. B. (2006). Impacts of ecotourism on short-beaked common dolphins (*Delphinus delphis*) in Mercury Bay, New Zealand. *Aquatic Mammals*, 32(1), 1-9. <https://doi.org/10.1578/AM.32.1.2006.1>
- Ostman-Lind, J., Driscoll-Lind, A. D., & Rickards, S. H. (2004). *Delphinid abundance, distribution and habitat use off the western coast of the island of Hawaii* (Administrative Report LJ-04-02C). La Jolla, CA: Southwest Fisheries Science Center.
- Read, A. J., & Murray, K. T. (2000). *Gross evidence of human-induced mortality in small cetaceans* (NOAA Technical Memo NMFS-OPR-15). Washington, DC: National Oceanic and Atmospheric Administration.
- Rehtanz, M., Ghim, S., Rector, A., Van Ranst, M., Fair, P. A., Bossart, G. D., & Jenson, A. B. (2006). Isolation and characterization of the first American bottlenose dolphin papillomavirus: *Tursiops truncatus* papillomavirus type 2. *Journal of General Virology*, 87, 3559-3565. <https://doi.org/10.1099/vir.0.82388-0>
- Reiderson, T. H., McBain, J., House, C., King, D. P., Stott, J. L., Kraft, A., . . . Lipscomb, T. P. (1998). Morbillivirus infection in stranded common dolphins from the Pacific Ocean. *Journal of Wildlife Diseases*, 34, 771-776. <https://doi.org/10.7589/0090-3558-34.4.771>
- Reif, J. S., Peden-Adams, M. M., Romano, T. A., Rice, C. D., Fair, P. A., & Bossart, G. D. (2009). Immune dysfunction in Atlantic bottlenose dolphins (*Tursiops truncatus*) with lobomycosis. *Medical Mycology*, 47, 125-135. <https://doi.org/10.1080/13693780802178493>
- Reif, J. S., Mazzoil, M. S., McCulloch, S. D., Varela, R. A., Goldstein, J. D., Fair, P. A., & Bossart, G. D. (2006). Lobomycosis in Atlantic bottlenose dolphins from the Indian River Lagoon, Florida. *Journal of the American Veterinary Medical Association*, 228, 104-108. <https://doi.org/10.2460/javma.228.1.104>
- Riggin, J., & Maldini, D. (2010). Photographic case studies of skin conditions in wild-ranging bottlenose dolphin (*Tursiops truncatus*) calves. *Journal of Marine Animals and Their Ecology*, 3, 5-9.
- Rowe, L. E., Currey, R. J. C., Dawson, S. M., & Johnson, D. (2010). Assessment of epidermal condition and calf size of Fiordland bottlenose dolphin *Tursiops truncatus* populations using dorsal fin photographs and photogrammetry. *Endangered Species Research*, 11, 83-89. <https://doi.org/10.3354/esr00256>
- Rowe, S. J. (2007). *A review of methodologies for mitigating incidental catch of protected marine mammals* (Department of Conservation Research and Development Series 283). Wellington: New Zealand Department of Conservation.
- Sanino, G. P., Van Bresse, M., Van Waerebeek, K., & Pozo, N. (2014). Skin disorders of coastal dolphins at Añihué Reserve, Chilean Patagonia: A matter of concern. *Boletín del Museo Nacional de Historia Natural*, 63, 127-157.
- Scott, E. M., Mann, J., Watson-Capps, J. J., Sargeant, B. L., & Connor, R. C. (2005). Aggression in bottlenose dolphins: Evidence for sexual coercion, male-male competition, and female tolerance through analysis of tooth-rake marks and behaviour. *Behaviour*, 142, 21-44. <https://doi.org/10.1163/1568539053627712>
- Sierra, E., Fernandez, A., Espinosa de los Monteros, A., Arbelo, M., Diaz-Delgado, J., Andrada, M., & Herraiz, P. (2014). Histopathological muscle findings may be essential for a definitive diagnosis of suspected sharp trauma associated with ship strikes in stranded cetaceans. *PLOS ONE*, 9, e88780. <https://doi.org/10.1371/journal.pone.0088780>
- Silva, M., & Sequeira, M. (2003). Patterns in the mortality of common dolphins (*Delphinus delphis*) on the Portuguese coast, using stranding records, 1975-1998. *Aquatic Mammals*, 29(1), 88-98.
- Steiger, G. H., Calambokidis, J., Straley, J. M., Herman, L. M., Cerchio, S., Salden, D. R., . . . Ford, J. K. B. (2008). Geographic variation in killer whale attacks on humpback whales in the North Pacific: Implications for predation pressure. *Endangered Species Research*, 4, 247-256. <https://doi.org/10.3354/esr00078>
- Stockin, K. A., & Orams, M. B. (2009). The status of common dolphins (*Delphinus delphis*) within New Zealand waters. *Journal of Cetacean Research and Management*, 61, 1-13.
- Stockin, K. A., Amaral, A. R., Latimer, J., Lambert, D. M., & Natoli, A. (2014). Population genetic structure and taxonomy of the common dolphin (*Delphinus* sp.) at its southernmost range limit: New Zealand waters. *Marine Mammal Science*, 30, 44-63. <https://doi.org/10.1111/mms.12027>
- Stockin, K. A., Lusseau, D., Binedell, V., Wiseman, N., & Orams, M. B. (2008a). Tourism affects the behavioural budget of the common dolphin *Delphinus* sp. in the

- Hauraki Gulf, New Zealand. *Marine Ecology Progress Series*, 355, 287-295. <https://doi.org/10.3354/meps07386>
- Stockin, K. A., Pierce, G. J., Binedell, V., Wiseman, N., & Orams, M. B. (2008b). Factors affecting the occurrence and demographics of common dolphins (*Delphinus* sp.) in the Hauraki Gulf, New Zealand. *Aquatic Mammals*, 34(2), 200-211. <https://doi.org/10.1578/AM.34.2.2008.200>
- Stockin, K. A., Wiseman, N., Hartman, A., Moffat, N., & Roe, W. D. (2008c). Use of radiography to determine age class and assist with the post-mortem diagnostics of a Bryde's whale (*Balaenoptera brydei*). *New Zealand Journal of Marine and Freshwater Research*, 42, 307-313. <https://doi.org/10.1080/00288330809509958>
- Stockin, K. A., Duignan, P. J., Roe, W. D., Meynier, L., Alley, M., & Fetterman, T. (2009). Causes of mortality in stranded common dolphins (*Delphinus* sp.) from New Zealand waters between 1998 and 2008. *Pacific Conservation Biology*, 15, 217-227. <https://doi.org/10.1071/PC090217>
- Thompson, F. N., Abraham, E. R., & Berkenbusch, K. (2013). Common dolphin (*Delphinus delphis*) bycatch in New Zealand commercial trawl fisheries. *PLOS ONE*, 8, e64438. <https://doi.org/10.1371/journal.pone.0064438>
- Thompson, P. M., & Hammond, P. S. (1992). The use of photography to monitor dermal disease in wild bottlenose dolphins (*Tursiops truncatus*). *Ambio*, 21, 135-137.
- Tyne, J. A., Pollock, K. H., Johnston, D. W., & Bejder, L. (2014). Abundance and survival rates of the Hawai'i Island associated spinner dolphin (*Stenella longirostris*) stock. *PLOS ONE*, 9, e86132. <https://doi.org/10.1371/journal.pone.0086132>
- Van Bressem, M. F., & Van Waerebeek, K. (1996). Epidemiology of poxvirus in small cetaceans from the eastern South Pacific. *Marine Mammal Science*, 12, 371-382. <https://doi.org/10.1111/j.1748-7692.1996.tb00590.x>
- Van Bressem, M. F., de Oliveira Santos, M. C., & de Faria Oshima, J. E. (2009a). Skin diseases in Guiana dolphins (*Sotalia guianensis*) from the Paranaguá estuary, Brazil: A possible indicator of a compromised marine environment. *Marine Environmental Research*, 67, 63-68. <https://doi.org/10.1016/j.marenvres.2008.11.002>
- Van Bressem, M. F., Gaspar, R., & Aznar, F. J. (2003). Epidemiology of tattoo skin disease in bottlenose dolphins *Tursiops truncatus* from the Sado Estuary, Portugal. *Diseases of Aquatic Organisms*, 56, 171-179. <https://doi.org/10.3354/dao056171>
- Van Bressem, M. F., Shirakihara, M., & Amano, M. (2012). Cutaneous nodular disease in a small population of Indo-Pacific bottlenose dolphins, *Tursiops aduncus*, from Japan. *Marine Mammal Science*, 29, 525-532. <https://doi.org/10.1111/j.1748-7692.2012.00589.x>
- Van Bressem, M. F., Van Waerebeek, K., & Bennett, M. (2006a). Orthopoxvirus neutralising antibodies in small cetaceans from the Southeast Pacific. *Latin American Journal of Aquatic Mammals*, 5, 49-54. <https://doi.org/10.5597/lajam00091>
- Van Bressem, M. F., Van Waerebeek, K., & Raga, J. A. (1999a). A review of virus infections of cetaceans and the potential impact of morbilliviruses, poxviruses and papillomaviruses on host population dynamics. *Diseases of Aquatic Organisms*, 38, 53-65. <https://doi.org/10.3354/dao038053>
- Van Bressem, M., Kastelein, R., Flamant, P., & Orth, G. (1999b). Cutaneous papillomavirus infection in a harbour porpoise (*Phocoena phocoena*) from the North Sea. *Veterinary Record*, 144, 592-593. <https://doi.org/10.1136/vr.144.21.592>
- Van Bressem, M. F., Van Waerebeek, K., Piérard, G., & Desaintes, C. (1996). Genital and lingual warts in small cetaceans from coastal Peru. *Diseases of Aquatic Organisms*, 26, 1-10. <https://doi.org/10.3354/dao026001>
- Van Bressem, M., Minton, G., Collins, T., Willson, A., Baldwin, R., & Van Waerebeek, K. (2015). Tattoo-like skin disease in the endangered subpopulation of the humpback whale, *Megaptera novaeangliae*, in Oman (Cetacea: Balaenopteridae). *Zoology in the Middle East*, 61, 1-8. <https://doi.org/10.1080/09397140.2014.994316>
- Van Waerebeek, K., Baker, A. N., Félix, F., Gedamke, J., Iñiguez, M., Sanino, G. P., . . . Wang, Y. (2007). Vessel collisions with small cetaceans worldwide and with large whales in the Southern Hemisphere: An initial assessment. *Latin American Journal of Aquatic Mammals*, 6, 43-69. <https://doi.org/10.5597/lajam00109>
- Van Bressem, M. F., Raga, J. A., Di Guardo, G., Jepson, P. D., Duignan, P. J., Siebert, U., . . . Van Waerebeek, K. (2009b). Emerging infectious diseases in cetaceans worldwide and the possible role of environmental stressors. *Diseases of Aquatic Organisms*, 86, 143-157. <https://doi.org/10.3354/dao02101>
- Van Bressem, M., Van Waerebeek, K., Aznar, F. J., Raga, J. A., Jepson, P. D., Duignan, P., . . . Baker, J. R. (2009c). Epidemiological pattern of tattoo skin disease: A potential general health indicator for cetaceans. *Diseases of Aquatic Organisms*, 85, 225-237. <https://doi.org/10.3354/dao02080>
- Van Bressem, M. F., Van Waerebeek, K., Jepson, P. D., Raga, J. A., Duignan, P. J., Nielsen, O., . . . Barrett, T. (2001). An insight into the epidemiology of dolphin morbillivirus worldwide. *Veterinary Microbiology*, 81, 287-304. [https://doi.org/10.1016/S0378-1135\(01\)00368-6](https://doi.org/10.1016/S0378-1135(01)00368-6)
- Van Bressem, M. F., Van Waerebeek, K., Montes, D., Kennedy, S., Reyes, J. C., Garcia-Godos, I. A., . . . Alfaro-Shigueto, J. (2006b). Diseases, lesions and malformations in the long-beaked common dolphin *Delphinus capensis* from the Southeast Pacific. *Diseases of Aquatic Organisms*, 68, 149-165. <https://doi.org/10.3354/dao068149>
- Van Bressem, M., Van Waerebeek, K., Reyes, J., Félix, F., Echegaray, M., Siciliano, S., . . . Frago, A. B. (2007). A preliminary overview of skin and skeletal diseases and traumata in small cetaceans from South American waters. *Latin American Journal of Aquatic Mammals*, 6, 1-26. <https://doi.org/10.5597/lajam00108>

- Weir, J. S., Deutsch, S. M., & Pearson, H. C. (2010). Dusky dolphin calf rearing. In B. Würsig & M. Würsig (Eds.), *The dusky dolphin: Master acrobat off different shores* (pp. 177-193). Amsterdam, The Netherlands: Elsevier, Academic Press. <https://doi.org/10.1016/B978-0-12-373723-6.00009-6>
- Wilson, B., Thompson, P. M., & Hammond, P. S. (1997). Skin lesions and physical deformities in bottlenose dolphins in the Moray Firth: Population prevalence. *Ambio*, 26, 243-247.
- Wilson, B., Grellier, K., Hammond, P. S., Brown, G., & Thompson, P. M. (2000). Changing occurrence of epidermal lesions in wild bottlenose dolphins. *Marine Ecology Progress Series*, 205, 283-290. <https://doi.org/10.3354/meps205283>
- Wilson, B., Arnold, H., Bearzi, G., Fortuna, C. M., Gaspar, R., Ingram, S., . . . Hammond, P. S. (1999). Epidermal diseases in bottlenose dolphins: Impacts of natural and anthropogenic factors. *Proceedings of the Royal Society of London Series B*, 266, 1077-1083. <https://doi.org/10.1098/rspb.1999.0746>
- Wright, A. J., Deak, T., & Parsons, E. C. M. (2008). Concerns related to chronic stress in marine mammals. *Report of the 61st Scientific Committee of the International Whaling Commission* (SC/61/E16).
- Würsig, B., & Jefferson, T. A. (1990). Methods of photo-identification for small cetaceans. *Report of the International Whaling Commission, Special Issue 12*, 43-52.
- Würsig, B., & Würsig, M. (1977). The photographic determination of group size, composition, and stability of coastal porpoises (*Tursiops truncatus*). *Science*, 198, 755-756. <https://doi.org/10.1126/science.198.4318.755>
- Yang, W., Chang, W., Kwong, K., Yao, Y., & Chou, L. (2013). Prevalence of epidermal conditions in critically endangered Indo-Pacific humpback dolphins (*Sousa chinensis*) from the waters of western Taiwan. *Pakistan Veterinary Journal*, 33, 505-509.